

Ultrasound-guided Compression Repair of Post Catheterisation Femoral Artery Pseudoaneurysm: A Retrospective Study from a Tertiary Cardiac Institute

MILIN N GARACHH¹, YASHPAL R RANA², MEGHA M SHETH³, DINESH L PATEL⁴, SAMIR G PATEL⁵, SHREYA K VORA⁶

ABSTRACT

Introduction: Femoral Artery Pseudoaneurysm (FAP) is a rare complication after catheterisation however due to huge workload of interventional procedures in a nodal cardiac institute; they are seen with relatively increasing frequency.

Aim: To share high volume cardiac institute's experience of Ultrasound-Guided Compression Repair (UGCR) technique, results and probable predictive factors of failed compression.

Materials and Methods: A retrospective study was conducted from 2012 to 2019 in which 310 patients diagnosed with FAP on ultrasound study were enrolled. All the patients who were diagnosed on same day of the procedure were given tight compression bandage and re-evaluated after 24 hours to look for presence or absence of spontaneous thrombosis. Those patients in whom pseudoaneurysm were still present 24 hours after the procedure were given compression. Manual compression was given with a 10 MHz linear probe until complete thrombosis was achieved or maximum four cycles were attempted before labelling patient as failure. In those patients where complete thrombosis was achieved, follow-up study was obtained at 24 hours and after one month to detect any recurrence. All statistical studies were carried out using

IBM SPSS program version 20. Quantitative variables were expressed as mean±standard deviation and qualitative variables were expressed as percentage (%).

Results: Out of 310 pseudoaneurysms, 53 of them were of small size and thrombosed spontaneously on 24 hours follow-up and tight compression bandage and seven patients fell in exclusion criteria. Remaining 250 patients were attempted for UGCR. Successful thrombosis of the pseudoaneurysm was achieved in 235 (94%) patients. The mean largest dimension of the pseudoaneurysms sac was 3.5 cm (range 1-8 cm) and mean sac area was 9 cm² (range 1-36 cm²). The mean length of pseudoaneurysm neck was 11 mm (1-26 mm) while mean width of neck was 2.3 mm (range 0.5-6 mm). The mean compression time of the successful compressions was 26 minutes (range 6-110 min). Successful thrombosis of the pseudoaneurysm was achieved in <60° angle (97.1%) compare to >60° angle (27.3%).

Conclusion: UGCR is a safe, reliable and cost-effective treatment for post catheterisation FAP. Width, and angle of the pseudoaneurysm neck were major predictive factor of technical success.

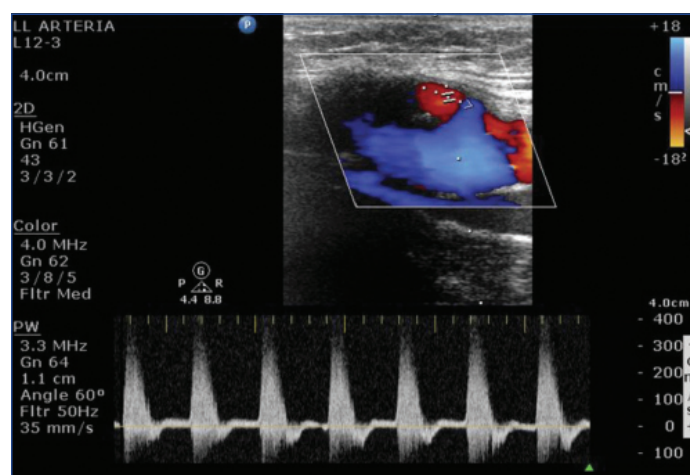
Keywords: Cardiac catheterisation, Interventional procedures, Successful thrombosis

INTRODUCTION

The Femoral Artery Pseudoaneurysm (FAP) is an iatrogenic complication occurring at the femoral arterial puncture site during invasive cardiovascular procedures. Various studies have observed their incidence to be 0.1% to 0.2% for diagnostic angiograms and 0.8% to 2.2% for interventional procedures [1,2]. The recent rise in incidence of FAP has been attributed to more frequent use of thrombolytics, anti-platelets, anti-coagulants and large bore cannulas for interventional procedures [1]. Pseudoaneurysms occurs if arterial puncture site does not seal, leading to leakage of arterial blood into the surrounding tissues, gets contained by haematoma and the pressure of surrounding tissues and form a perfused sac (the false lumen) connected to the supplying artery by a "neck" [3]. It can present as localised swelling or pulsatile haematoma, a new thrill or bruit, or marked pain or tenderness. Complications of pseudoaneurysms include rupture leading to catastrophic bleeding, local pain, infection, skin necrosis, distal embolisation, compression neuropathy, and distal limb ischaemia [3].

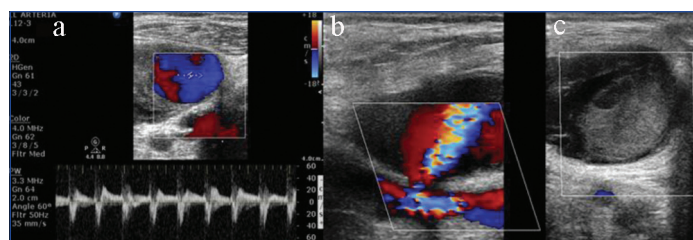
Ultrasound with colour doppler imaging is the modality of choice for diagnosis of pseudoaneurysm. Typical characteristics of pseudoaneurysm include colour flow within a tract leading from the artery to the sac, swirling colour flow within sac and a typical to-and-fro Doppler waveform ("the yin-yang sign") in the pseudoaneurysm

neck [Table/Fig-1,2a]. Morgan R and Belli AM in their study stated that colour Doppler ultrasound is 94% to 97% sensitive in diagnosing peripheral pseudoaneurysm [4].



[Table/Fig-1]: Doppler ultrasound image showing "the yin-yang sign" due to to-and-fro pattern of flow within pseudoaneurysm sac.

It is possible for small pseudoaneurysms (less than 2 cms in diameter) to thrombose spontaneously within four weeks [5], but this spontaneous resolution is unpredictable, and the watch-and-wait



[Table/Fig-2]: Doppler ultrasound image showing: a) "The yin-yang sign" due to to-and-fro pattern of flow within pseudoaneurysm sac; b) Femoral artery of origin with patent neck and pseudoaneurysm sac; c) Post successful compression completely thrombosed sac with no flow within.

policy may reduce patient's activity and delay discharge, prompting an early active management of most pseudoaneurysms. Fellmeth BD et al., first described UGCR [6]. Since then it has been proved to be a safe and cost-effective method for achieving pseudoaneurysm thrombosis, with a failure rate of 10-35% [6-8]. This article is aimed at sharing seven years' experience of performing UGCR to treat FAP in a research cardiac institute. Various predictive factors for successful versus failed UGCR are also discussed, though remain controversial. An attempt was made to include angle of neck in relation to underlying artery of origin as one of the predicting factors, and to the best of current available knowledge till date none of major studies have addressed it.

MATERIALS AND METHODS

A retrospective, observational study was conducted at UN Mehta Institute of Cardiology and Research Center, Ahmedabad, Gujarat, India from December 2012 to November 2019 after approval of the ethical committee of the institute (UNMICRC/ALLIED/2019/04.).

Inclusion Criteria: Out of 1,55,000 total femoral punctures performed for various diagnostic and therapeutic procedures by different operators during seven years period from December 2012 to November 2019, ultrasound were performed for evaluation of local site (groin region) in patients having local site swelling or pain or bruit on clinical examination were included. Chronic pseudoaneurysm (>28 days), were also enrolled.

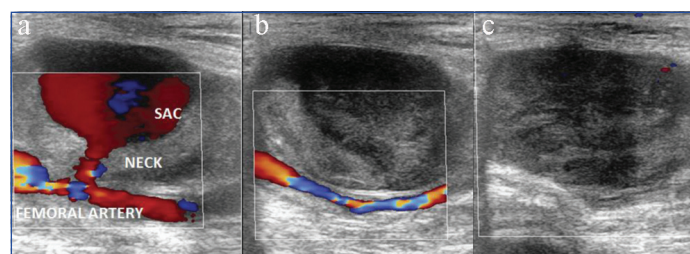
Exclusion Criteria: Patients with pseudoaneurysms above the inguinal ligament, presence of a puncture site infection, or a limb threatened by vascular compromise were excluded. Seven patients fell in exclusion criteria- five due to local site infection, one due to pseudoaneurysm above the inguinal ligament and one due to limb threatened by vascular compromise.

Total 310 pseudoaneurysms were detected out of 1,55,000 total femoral punctures (0.2% incidence). All the patients who were diagnosed on same day of the procedure were given tight compression bandage and re-evaluated after 24 hours to look for presence or absence of spontaneous thrombosis. Out of 310 pseudoaneurysms, 53 of them were of small size and thrombosed spontaneously on 24 hours follow-up and tight compression bandage.

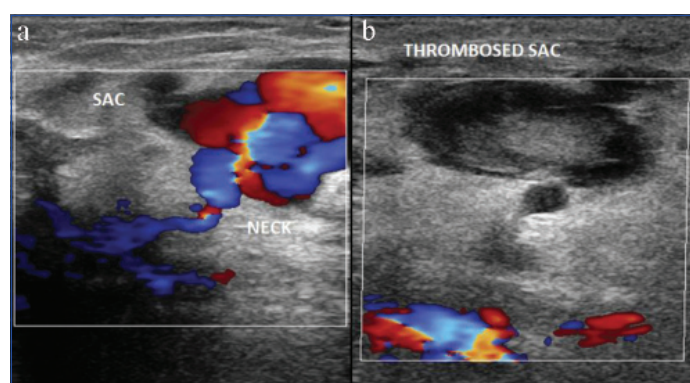
A high frequency of 10 MHz linear probe of colour ultrasound (Philips HD 15, USA) was used to confirm the diagnosis of a pseudoaneurysm. Local anaesthetic agent was used as and when required. Intravenous analgesics were not needed in any of patients. Manual compression was given with a 10 MHz linear probe to obliterate flow in the pseudoaneurysm neck while still allowing flow through the underlying femoral artery for 10 minutes intervals [Table/Fig-2b,c,3]. After some time the pseudoaneurysm was rechecked for occlusion and peripheral pulses were reassessed. If flow was still present, the procedure may be repeated at most three times (30 minutes' compression) in one cycle. A successful repair was considered when complete thrombosis of the sac was achieved [Table/Fig-4,5]. If complete thrombosis was not achieved, same cycle was repeated next day. Maximum four cycles were attempted before labelling patient as failure. A study by Huang TL et al., have attempted total

three cycles of 45 minutes duration ($45 \times 3 = 135$ minutes) [9]. In present study it was modified to 30 minutes per cycle to total four cycles ($30 \times 4 = 120$ minutes). In those patients where complete thrombosis was achieved, patients were confined to bed rest in the hospital for 24 hours with a compression bandage. Rechecking of the arterial flow was considered on the following day before discharge and after one month to detect any recurrence. No procedure related complications were encountered.

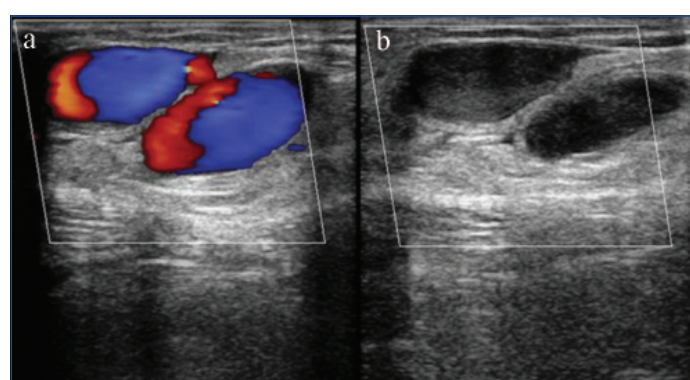
Age, gender, procedure performed, artery of origin, duration of the pseudoaneurysm, the size and area of the pseudoaneurysm sac,



[Table/Fig-3]: Doppler ultrasound image showing: a) Femoral artery of origin with patent neck and pseudoaneurysm sac; b) During compression no flow within sac while flow present within underlying femoral artery; c) Post successful compression completely thrombosed sac with no flow within.



[Table/Fig-4]: Doppler ultrasound image showing: a) Femoral artery of origin with patent neck and pseudoaneurysm sac; b) Post successful compression completely thrombosed sac with no flow within.



[Table/Fig-5]: Doppler ultrasound image showing: a) Femoral artery of origin with patent neck and pseudoaneurysm sac; b) Post successful compression completely thrombosed sac with no flow within.

the width and length (from the pseudoaneurysm to the origin from femoral artery) and angle of neck of the pseudoaneurysm and time required for complete thrombosis were evaluated.

STATISTICAL ANALYSIS

All statistical tests were carried out using IBM SPSS program version 20. Mean \pm SD values were used to express Quantitative variable and percentages were used to express Qualitative variable. Association between angle and neck width, duration of aneurysm and mean time of successful compressions was done using chi-square test.

RESULTS

The mean largest dimension of the pseudoaneurysms sac was 3.5 ± 1.83 cm (range 1-8 cm) and mean sac area was 9 ± 7.31 cm² (range 1-36 cm²) [Table/Fig-6].

Variables		N=250 (%) or Mean \pm SD
Gender	Male	135 (54)
	Female	115 (46)
Location	CFA	241 (96.4)
	SFA	8 (3.2)
	DFA	1 (0.4)
Side	Right	210 (84)
	Left	40 (18)
Success	Successful	235 (94)
	Failure	15 (6)
Age		60 \pm 7.84 years (Range: 41-70)
Sac size		3.5 \pm 1.83 cm (Range: 1-8 cm)
Sac area		9 \pm 7.31 cm ² (Range: 1-36 cm ²)
Neck width		2.3 \pm 1.15 mm (Range: 0.5-6 mm)
Neck length		11 \pm 6.07 mm (Range: 1-26 mm)
Duration of aneurysm		2 \pm 3.9 days (Range: 1-46 days)
Mean time required		26 \pm 25.27 min (Range: 6-110 min)
Procedure	Diagnostic coronary angiography	75 (30)
	Therapeutic coronary angiography with stent placement	140 (56)
	Therapeutic peripheral angiography	32 (12.8)
	Intra-Arterial Balloon Pump (IABP)	3 (1.2)

[Table/Fig-6]: Parameters of 250 patients who underwent UGCR.

CFA: Common femoral artery; SFA: Superficial femoral artery; DFA: Deep femoral artery

Successful thrombosis of the pseudoaneurysm was achieved in <60° angle (97.1%) compare to >60° angle (27.3%). The difference between two groups was statistically significant ($p < 0.0001$). Neck width, duration of aneurysm and mean time of successful compressions was also associated with <60° angle ($p < 0.0001$) [Table/Fig-7].

The mean compression time of the successful compressions was 26 \pm 25.27 minutes (range 6-110 minutes). Successful

	Angle <60° N=239	Angle >60° N=11	p-value*
Successful	232 (97.1)	3 (27.3)	<0.0001
Failure	7 (2.9)	8 (72.7)	
Sac size	3.5 \pm 1.85 cm	3.5 \pm 1.32 cm	1
Sac area	8.88 \pm 7.17 cm ²	11.55 \pm 10.06 cm ²	0.24
Neck width	2.24 \pm 1.1 mm	3.58 \pm 1.41 mm	<0.0001
Neck length	11.14 \pm 6.06 mm	7.91 \pm 5.67 mm	0.08
Duration of aneurysm	1.72 \pm 2.07 days	8.18 \pm 15.22 days	<0.0001
Mean time of successful compression	23.43 \pm 19.97 min	81.91 \pm 53.04 min	<0.0001

[Table/Fig-7]: Neck width, duration of aneurysm and mean time of successful compressions and their association with angle ($p < 0.0001$).

*Calculated by using chi-square test

thrombosis of the pseudoaneurysm was achieved in 235 (94%) patients. Of the 15 patients who underwent surgical treatment, 10 patients had failed UGCR, three failed due to development of local infection, one patient refused treatment after one UGCR cycle, one patient required ventilation due to worsening of his primary cardiac condition. Parameters of 15 UGCR failure group are summarised in [Table/Fig-8].

All 235 patients who had successful UGCR further had 24-hour and one month follow-up colour ultrasound and all of them were found to be asymptomatic with no evidence of recurrence.

DISCUSSION

UGCR of the pseudoaneurysm neck with simultaneous thrombin injection is currently the method of choice in many centres because of its ease, rapidity, and minimal discomfort, with success rate ranging between 86% and 100% [10].

In this study mean largest dimension of sac in success group was 3.5 cm and in failure group was 4.2 cm. According to Coley BD et al technical success was 87% for pseudoaneurysms whose dimension was 4 cm or less and it was only 62% for lesions more than 4 cm [11]. Similar findings was observed by Eisenberg et al., [3]. It is hypothesised that flow through a large sac tends to be greater than flow through a small sac and therefore difficult to obliterate completely. However, largest mean sac dimension with successful UGCR in this study was 8 cm and few <4 cm size sac had failed UGCR. No correlation between the pseudoaneurysm size and the therapeutic success were found in studies by Huang TL et al., [9] and in Schaub's series [12]. Mean neck length in

No.	Artery of origin	Compression time	Outcome	Largest sac dimension Mean-4.2 cm	Neck width Mean-4.4 mm	Neck length Mean-9 mm	Neck angle
1	CFA	120 min	Failure	4.5 cm	5.5 mm	1 mm	>60°
2	CFA	120 min	Failure	3 cm	4 mm	8 mm	>60°
3	CFA	120 min	Failure	6 cm	3.8 mm	10 mm	>60°
4	DFA	120 min	Failure	4 cm	4.3 mm	23 mm	<60°
5	CFA	120 min	Failure	2.5 cm	4.5 mm	2 mm	>60°
6	CFA	120 min	Failure	3.8 cm	5 mm	4 mm	>60°
7	SFA	120 min	Failure	4.3 cm	4.1 mm	5 mm	>60°
8	CFA	120 min	Failure	4.5 cm	3.9 mm	5 mm	>60°
9	CFA	120 min	Failure	3.8 cm	4.5 mm	15 mm	<60°
10	CFA	120 min	Failure	5.5 cm	4.4 mm	18 mm	<60°
11	CFA	Only 1 cycle attempted	Development of local site infection	2.8 cm	5.5 mm	9.5 mm	<60°
12	CFA	Only 1 cycle attempted	Development of local site infection	3 cm	5 mm	8.6 mm	<60°
13	CFA	Only 1 cycle attempted	Development of local site infection	4.3 cm	4.4 mm	7.2 mm	<60°
14	CFA	Only 1 cycle attempted	Patient refused	5 cm	4 mm	8.3 mm	<60°
15	CFA	Only 1 cycle attempted	Required ventilation due to worsening of his primary cardiac condition	6 cm	4.1 mm	10.4 mm	>60°

[Table/Fig-8]: Parameters of UGCR failure group.

CFA: Common femoral artery; SFA: Superficial femoral artery; DFA: Deep femoral artery

success group was 11 mm and in failure group was 9 mm. Schaub F et al., in his series noted that short length of the neck (<10 mm) is a factor which is likely to result in unsuccessful compression and in present study also same was observed [13]. The mean width of pseudoaneurysm neck in success group was 2.3 mm and in failure group was 4.4 mm. Various previous studies have concluded that wide pseudoaneurysm neck (>4 mm) is also a factor which is likely to result in unsuccessful compression [9,13].

This study explored the angle of neck in relation to underlying artery of origin as one of the predicting factors, and to the best of knowledge till date none of studies have addressed it. Cut-off value of <60° was associated with high success rate. In success group 232 patients had angle <60° and only 3 patients had angle >60°. In failure group, only seven patients had angle <60° and while eight patients had angle >60°.

None of the patients was asked to stop anticoagulants in this study and did not keep data of the International Normalised Ratio (INR) as almost all of patients had cardiac pathology requiring strict continuation of anticoagulants and many previous studies have failed to consider it to be significant factor in success of UGCR. Schaub F et al., reported a 54% success rate in patients who used anticoagulants (INR, 2.5-6.0) versus 93% in patients who did not use anticoagulants [12]. They showed no significant correlation between INR at the time of UGCR and the therapeutic success rate, with a p-value of 0.014 (in their series, p<0.01 was defined as significant).

The chronicity of a pseudoaneurysm will decrease the thrombogenicity of the track due to the development of endothelium. So previously pseudoaneurysm > 28-day-old has been regarded as untreatable by UGCR. However, many studies have shown that pseudoaneurysm age should not be considered as a predictive factor of technical success [3,10]. In this study, the mean duration of presentation in success group was two days while nine days in failure group. It was concluded that chronicity is not a predictive factor but chronic pseudoaneurysm require longer compression time. The mean time required for successful compression was 26 minutes in this study. While for those pseudoaneurysms >28 days, mean time was 60 minutes in this study. Factors like the presence of a large surrounding haematoma, associated arteriovenous fistula, the size of arterial sheath used and the presence of underlying femoral artery disease do not affect outcome [11,14]. Comparison of this study with two major studies' results are summarised in [Table/Fig-9].

Parameter assessed	Cox GS et al., [14]	Huang TL et al., [9]	Present study
Mean largest dimension	Mean: 2.2 cm Range: 0.5 to 5.2 cm	Mean: 3.6 cm Range: 1 to 9 cm	Mean: 3.5 cm Range: 1 to 8 cm
Sac area	Not studied	Mean: 7.3 cm ² Range: 0.5 to 31.5 cm ²	Mean: 9 cm ² Range: 1 to 36 cm ²
Duration of aneurysm	Mean: 7.6 days Range: 1 to 80 days	Not studied	Mean: 2 days Range: 1 to 46 days
Mean time required	Mean: 33 min Range: 10 to 120 min	Mean: 21.2 min Range: 8 to 45 min	Mean: 26 min Range: 6 to 110 min
Neck length	Not studied	Mean: 3.3 mm Range: 1.1 to 20.2 mm	Mean: 11 mm Range: 1 to 26 mm
Neck width	Not studied	Mean: 2.1 mm Range: 1 to 5 mm	Mean: 2.3 mm Range: 0.5-6 mm
Neck angle	Not studied	Not studied	<60°: 222 >60°: 13
Success rate	94%	90.5%	94%

[Table/Fig-9]: Comparison of results with various studies [9,14].

Though UGCR is overall a safe procedure, Eisenberg L et al., had reported a 3.6% complication rate [3]. Common complications include acute enlargement of the pseudoaneurysm, rupture, vasovagal response, deep vein thrombosis, acute hypertension, and angina. Femoral artery thrombosis after simultaneous temporary occlusion of the underlying artery had also been reported previously [6]. No procedure-related complications were encountered in this study. However, due to large number of participants this study offer conclusive results and a study of new parameter- angle of neck of pseudoaneurysm adds new knowledge in current concept.

Limitation(s)

This study may have few limitations: 1) Patients coagulation status was not corrected; 2) All the UGCR was not carried out by single radiologist; 3) It is possible that many of small lesions may have gone undiagnosed or closed spontaneously so true incidence cannot be estimated reliably; 4) Comparative assessment of simple UGCR with UGCR of the neck and simultaneous thrombin injection was not done.

CONCLUSION(S)

In present study width and angle of pseudoaneurysm neck was found to be the most reliable predictive factor for technical success and UGCR procedure is considered as safe, cheap and reliable technique to treat post procedure FAP.

REFERENCES

- [1] Messina LM, Brothers TE, Wakefield TW, Zelenock GB, Lindenauer SM, Greenfield LJ, et al. Clinical characteristics and surgical management of vascular complications in patients undergoing cardiac catheterisation: Interventional versus diagnostic procedures. *J Vasc Surg.* 1991;13:593-600.
- [2] Babu SC, Piccorelli GO, Shah PM, Stein JH, Clauss RH. Incidence and results of arterial complications among 16350 patients undergoing cardiac catheterisation. *J Vascular Surg.* 1989;10:113-16.
- [3] Eisenberg L, Paulson EK, Kliever MA, Hudson MP, DeLong DM, Carroll BA. Sonographically guided compression repair of pseudoaneurysms: Further experience from a single institution. *AJR Am J Roentgenol.* 1999;173:1567-73.
- [4] Morgan R, Belli AM. Current treatment methods for postcatheterisation pseudoaneurysms. *J Vasc Interv Radiol.* 2003;14:697-710.
- [5] Johns JP, Pupa Jr LE, Bailey SR. Spontaneous thrombosis of iatrogenic femoral artery pseudoaneurysms: Documentation with colour Doppler and two-dimensional ultrasonography. *J Vase Surg.* 1991;14:24-29.
- [6] Fellmeth BD, Roberts AC, Bookstein JJ, Freischlag JA, Forsythe JR, Buckner NK, et al. Postangiographic femoral artery injuries: Nonsurgical repair with US-guided compression. *Radiology.* 1991;178:671-75.
- [7] Paulson EK, Kliever MA, Hertzberg BS, Tcheng JE, McCann RL, Bowie JD, et al. Ultrasonographically guided manual compression of femoral artery injuries. *J Ultrasound Med.* 1995;14:653-59.
- [8] McNeil Nancy L, Timothy W, Clark I. Sonographically guided percutaneous thrombin injection versus sonographically guided compression for femoral artery pseudoaneurysms. *AJR.* 2001;176:459-62.
- [9] Huang TL, Liang HL, Huang JS, Yang TL, Chen YJ, Huang PY, et al. Ultrasound-guided compression repair of peripheral artery pseudoaneurysm: 8 years' experience of a single institute. *Journal of the Chinese Medical Association.* 2012;75:468-73.
- [10] Olsen DM, Rodriguez JA, Vranic M, Ramaiah V, Ravi R, Diethrich EB. A prospective study of ultrasound scan-guided thrombin injection of femoral pseudoaneurysm: A trend toward minimal medication. *J Vasc Surg.* 2002;36:779-82.
- [11] Coley BD, Roberts AC, Fellmeth BD, Valji K, Bookstein JJ, Hye RJ. Postangiographic femoral artery pseudoaneurysms: Further experience with US-guided compression repair. *Radiology.* 1995;194:307-11.
- [12] Schaub F, Theiss W, Busch R, Heinz M, Paschalidis M, Schomig A. Management of 219 consecutive cases of postcatheterisation pseudoaneurysm. *J Am Coll Cardiol.* 1997;30:670-75.
- [13] Schaub F, Theiss W, Heinz M, Zigel M, Schomig A. New aspects in ultrasound-guided compression repair of postcatheterisation femoral artery injuries. *Circulation.* 1994;90:1861-65.
- [14] Cox GS, Young JR, Gray BR, Grubb MW, Hertzner NR. Ultrasound-guided compression repair of postcatheterisation pseudoaneurysms: Results of treatment in one hundred cases. *J Vasc Surg.* 1994;19:683-86.

PARTICULARS OF CONTRIBUTORS:

1. Consultant Radiologist, Department of Radiology, U N Mehta Institute of Cardiology and Research Centre, Ahmedabad, Gujarat, India.
2. Consultant Radiologist, Department of Radiology, U N Mehta Institute of Cardiology and Research Centre, Ahmedabad, Gujarat, India.
3. Consultant Radiologist, Department of Radiology, U N Mehta Institute of Cardiology and Research Centre, Ahmedabad, Gujarat, India.
4. Consultant Radiologist and Head, Department of Radiology, U N Mehta Institute of Cardiology and Research Centre, Ahmedabad, Gujarat, India.
5. Consultant Radiologist, Department of Radiology, U N Mehta Institute of Cardiology and Research Centre, Ahmedabad, Gujarat, India.
6. Resident, Department of Radiology, Civil Hospital, BJ Medical College, Ahmedabad, Gujarat, India.

NAME, ADDRESS, E-MAIL ID OF THE CORRESPONDING AUTHOR:

Dr. Yashpal R Rana,
U N Mehta Institute of Cardiology and Research Centre, Affiliated to B.J. Medical
College, Civil Hospital, Asarwa, Ahmedabad-380016, Gujarat, India.
E-mail: yashpal_my2@yahoo.co.in

PLAGIARISM CHECKING METHODS: [\(Jan H et al.\)](#)

- Plagiarism X-checker: Dec 21, 2019
- Manual Googling: Mar 23, 2020
- iThenticate Software: Mar 28, 2020 (10%)

ETYMOLOGY: Author Origin**AUTHOR DECLARATION:**

- Financial or Other Competing Interests: None
- Was Ethics Committee Approval obtained for this study? Yes
- Was informed consent obtained from the subjects involved in the study? Yes
- For any images presented appropriate consent has been obtained from the subjects. Yes

Date of Submission: **Dec 19, 2019**Date of Peer Review: **Feb 08, 2020**Date of Acceptance: **Mar 24, 2020**Date of Publishing: **Apr 01, 2020**